


PRESENTING CLINICAL SIGNS

DATE History: Experienced two seizure-like episodes in the car on the way home from the vet yesterday.
No murmur.

2/9/22

ECHOCARDIOGRAPHIC FINDINGS

2D, M-mode, and Doppler study.

PERFORMED BY:

Dr. Meredith Swart

INTERPRETED BY

Keith Blass, DVM,
MS, DACVIM
(Cardiology)

Left atrial size is normal. The mitral valve is normal. Left ventricular dimensions are normal. Left ventricular systolic function is hyperdynamic. The aorta and aortic valve are normal. Right atrial and right ventricular dimensions are normal. The tricuspid valve appears normal, though trace tricuspid regurgitation is present. TR velocity does not suggest the presence of pulmonary hypertension. The pulmonary artery and pulmonic valve are normal. No shunting lesions are visualized. No pericardial effusion or cardiac masses are seen.

PATIENT

Junior Wagner

LA - 28.8 mm
IVSd - 8.7 mm
LVPWd - 8.6 mm
LVIDd - 25.8 mm
LVIDs - 14.1 mm
FS - 45.3%
LVOT - 0.82 m/s
RVOT - 0.92 m/s
TR - 2.57 m/s

SPECIES

Canine

ASSESSMENT/RECOMMENDATIONS

Normal echocardiogram

BREED

Bichon Mix

This examination demonstrates no evidence of structural heart disease, as trace tricuspid regurgitation can be considered a normal physiologic variant. As such, no reason for Junior's seizure-like episodes is appreciated in the image set. If syncope is suspected, possible causes include vasovagal syncope and an intermittent arrhythmia.

SEX

An ECG and/or Holter/event monitor is recommended if Junior experiences additional episodes.

MN

No therapy is recommended based on this exam.

AGE

14 y

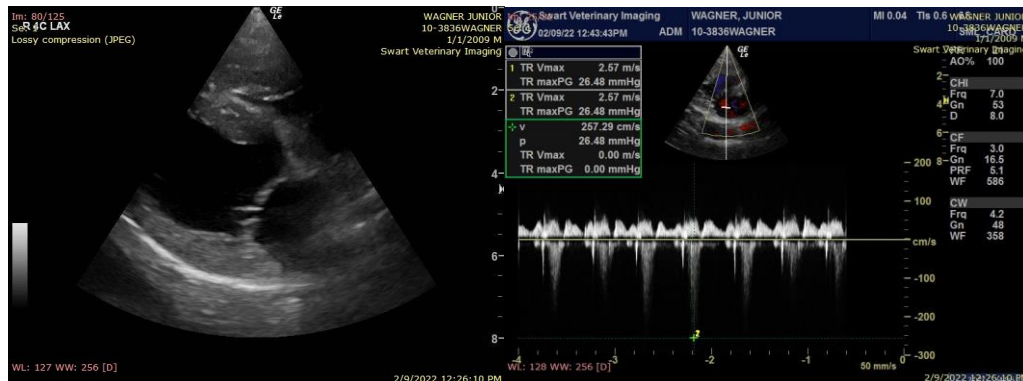
A recheck echocardiogram is recommended if new physical exam and/or clinical abnormalities suggestive of cardiac dysfunction develop.

WEIGHT

15 lb

HOSPITAL NAME

Swart Veterinary
Imaging



The information and recommendations provided are based on the images presented by the referring veterinarian. No evaluation can be communicated regarding pathology that was not visible in the image/video clips provided.

REFERRING VET

Dr. Swart



DATE

Thank you for this referral. If the clinical or image interpretation does not parallel your findings or if I can be of any further assistance please contact me.

2/9/22

PERFORMED BY:

Keith Blass, DVM, MS, DACVIM (Cardiology)
KeithBlass@gmail.com
631-804-5754

Dr. Meredith Swart

INTERPRETED BY

Keith Blass, DVM,
MS, DACVIM
(Cardiology)

PATIENT

Junior Wagner

SPECIES

Canine

BREED

Bichon Mix

SEX

MN

AGE

14 y

WEIGHT

15 lb

HOSPITAL NAME

Swart Veterinary
Imaging

REFERRING VET

Dr. Swart